

Functional Outcome After Open Reduction and Internal Fixation in Intraarticular Distal Humerus Fracture: A Case Report

Antonius H Pakpahan, Rashida S Djatnika

Departemen Ortopedi dan Traumatologi Rumah Sakit Daerah Bekasi, Indonesia

E-mail: rashidasabahat12@gmail.com

*Correspondence: rashidasabahat12@gmail.com

KEYWORDS	ABSTRACT
reduction; and internal fixation; distal humerus fractures	The purpose of this study is to find out functional outcome after open reduction and internal fixation in intraarticular distal humerus fracture. The method used is the case report method. The purpose of this method is to present in-depth information about a particular case, including symptoms, diagnosis, treatment, and results. A 51-years-old male patient presented to the emergency department after injuring his right elbow following motorcycle accident. He had suffered pain, swelling and bruise on his right elbow without neurovascular injury or external wound. Anteroposterior and lateral x rays and 3D CT scan of the right elbow joint showed simple articular and comminuted metaphyseal classified as type 13-C2. The normal range of flexion-extension of the elbow is 0°–145°. The functional range of motion required for daily activities is 30°–130° of flexion-extension and 50° of supination to 50° of pronation. Distal humerus fracture management requires a carefully planned approach. Surgical management by internal fixation is the treatment of choice for these fractures considered for a satisfactory function.

Attribution- ShareAlike 4.0 International (CC BY-SA 4.0)



Introduction

Distal humerus fractures in the adult population represent about 2% of all fractures and 33% of all humerus fractures. They are usually the result of high-energy trauma in the young population and low-energy falls in the more elderly patient (Crean TE, 2022). The management of distal humerus fractures is considered challenging and technically demanding, because of the complexity of the regional anatomy and the multi-fragmentary pattern of injury (Savvidou et al., 2018). Open reduction and internal fixation (ORIF) is the treatment of choice for these fractures. The goals are to restore articular congruity and bone alignment whilst providing rigid, stable fixation that enables early active motion and reach functional elbow, which requiring 30 to 130 degrees range of motion (Attum B, 2022; Beazley et al., 2017).

Despite the goal achieved regarding elbow surgery, the postoperative complication rates are reported as high as 35%, including mechanical failure, nerve palsy,

Functional Outcome After Open Reduction and Internal Fixation in Intraarticular Distal Humerus Fracture: A Case Report

stiffness, heterotopic ossification, non-union, malunion, infection, and post-traumatic arthritis were recorded (Patel et al., 2020).

Here, we reported a case of type c fracture of distal humerus treated surgically in our institution and the following evaluation of the functional and radiological results of open reduction and internal fixation using precontoured anatomical locking LCP plate system for intraarticular distal humerus fractures (Beharrie et al., 2004).

Case Presentation

A 51-years-old male patient presented to the emergency department after injuring his right elbow following motorcycle accident. He had suffered pain, swelling and bruise on his right elbow without neurovascular injury or external wound. Anteroposterior and lateral x rays and 3D CT scan of the right elbow joint showed simple articular and comminuted metaphyseal classified as type 13-C2.

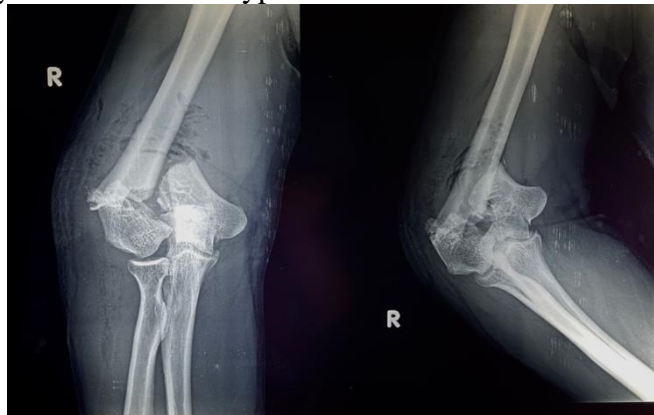

Figure 1 pre-operative x ray Anteroposterior and Lateral view

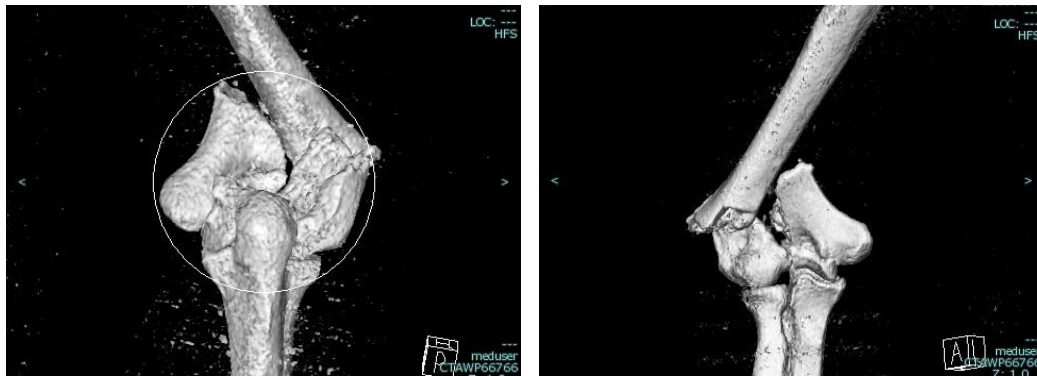


Figure 1. Preoperative CT scan 3D showed simple articular fracture, simple metaphyseal fracture with marked displacement

Surgical Procedure

After the induction of general anesthesia, the patient was placed in the supine position with elbow flexion and forearm crossing chest, a longitudinal incision was made along the midline of the posterior aspect of the elbow and medially curved at the olecranon tip. The ulnar nerve was dissected carefully and protected by a rubber strip, and then, a V-shaped osteotomy was performed in the proximal olecranon (Van Dreumel et al., 2015). The proximal bone fragment and triceps muscle were flipped upward to expose the distal part of the humerus. The trochlear and capitellar articular surfaces of the distal humerus were aligned with the olecranon and radial head articular surfaces. We stabilized the distal fragments using K-wires (Kirschner wires) for a temporary reduction.

Then, the intercondylar fracture was converted to a supracondylar fracture of the distal humerus. Next, the humeral shaft and both columns were reduced. To optimize the stability of the bony structure, the distal humerus was stabilized using anatomical locking compression plates via a perpendicular configuration. Several K-wires were left for the fixation of the tiny fragments. After internal fixation, the elbow joint exhibited an almost full range of motion during passive flexion and extension. Finally, the olecranon osteotomy site was reduced and fixed by tension band wires. We performed subcutaneous transposition of the ulnar nerve using soft tissue sling to prevent direct contact and irritation from the hardware. After the surgery, standard AP and lateral radiographs of the elbow joint were taken to evaluate the quality of reconstruction. The drainage tube was removed 24 h after surgery (Peng et al., 2019).

Active exercises of the hand and wrist, isometric contractions of the biceps and forearm muscles, and active elbow flexion and extension exercises were initiated on the second day after surgery.

Follow-Up Results

The patient underwent routine active self-exercise at home for three months after surgery. The radiographs showed the presence of callus passing through the fracture lines. Ten months follow-up after surgery, radiographic showed denser callus and satisfaction degree of elbow range of motion which is flexion 130° and extension 10° (Massoud & Naam, 2012). The patient can perform pronation and supination of his forearm normally without pain. He could do his previous job as a chef and the fragments fixed by perpendicular anatomical locking plate configuration and olecranon osteotomy site was reduced and fixed by tension band wires with no pain.

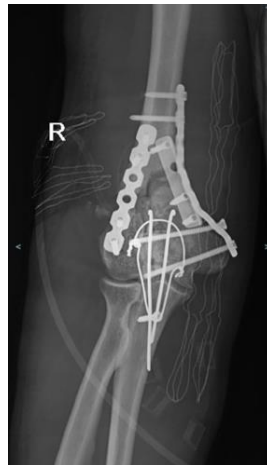

Figure 3 post-operative AP view x-ray.

Shown fracture Figure 2 post-operative AP view x-ray. Shown fracture fragments fixed by perpendicular anatomical locking plate configuration and olecranon osteotomy site was reduced and fixed by tension band wires.

Functional Outcome After Open Reduction and Internal Fixation in Intraarticular Distal Humerus Fracture: A Case Report

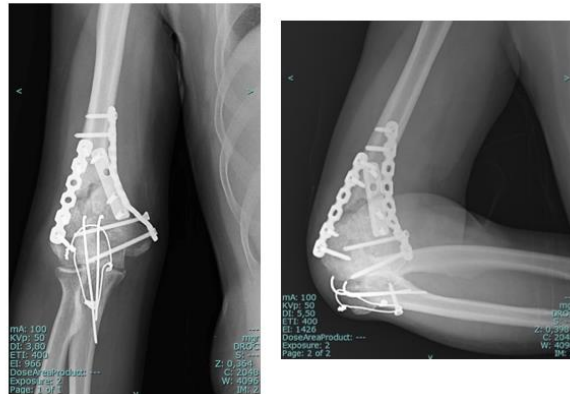


Figure 4 post operative x ray AP and L view 3 months after fixation

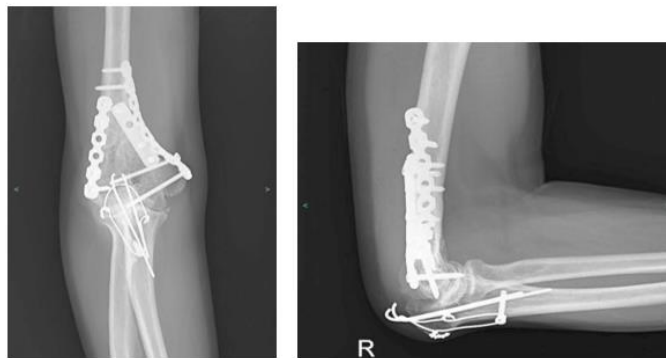


Figure 5 post operative x ray AP and L view, 9 months after fixation

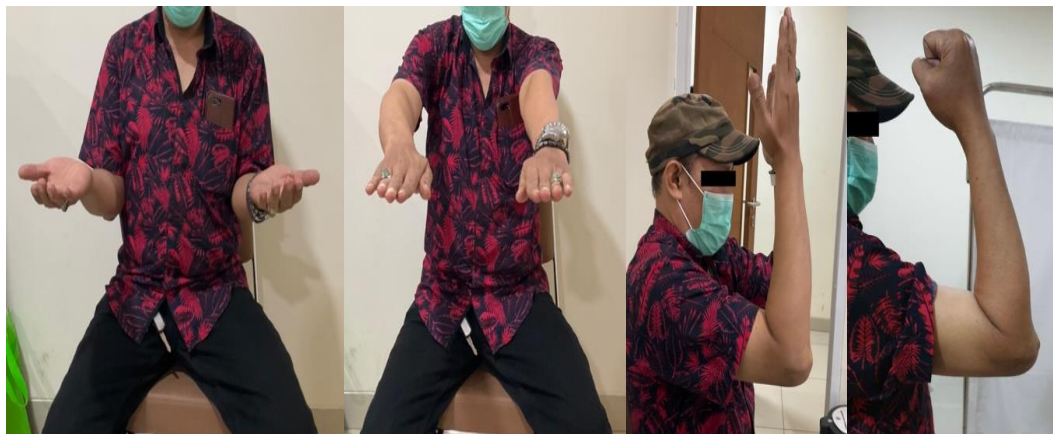

Figure 6 ROM elbow 10 months after fixation

Research Methods

The method used is the case report method. The purpose of this method is to present in-depth information about a particular case, including symptoms, diagnosis, treatment, and results.

Results and Discussions

Humeral fractures are complex injuries that require a carefully planned approach, when considering surgical fixation, to restore anatomy and achieve good functional outcomes. Successful management of distal humerus fractures depends on the correct reduction of the fracture, Surgical treatment become the gold standard while conservative treatment has been playing only a minor role in the management of fractures of the distal humerus. Non-operative treatment seems to be only advisable in cases of non-displaced fractures, in patients being assessed not fit for surgery, or as a temporary treatment in the elderly before arthroplasty to avoid stiffening and heterotopic ossification (Amir et al., 2016).

Open reduction and internal fixation (ORIF) is the treatment of choice for these fractures. It is indicated in open fractures, vascular injury requiring repair, brachial plexus injury, floating elbow (ipsilateral forearm fracture), and compartment syndrome. Other relative indications include polytrauma, bilateral humerus fractures, pathologic fractures, and burns or soft tissue injury precluding bracing.⁴ Achieving rigid internal fixation and anatomical reconstruction by restoring the two columns and the articular surface is essential for allowing early motion, adequate bone healing and avoiding future cartilage degeneration.

In elderly patients over 65 years with type C fracture, with low bone quality due to osteoporosis, total elbow arthroplasty (TEA) is often considered to be a better choice compared to ORIF. Nonetheless, ORIF is still considered the gold standard for the treatment of fractures of the distal humerus.

However, the complication of ORIF of distal humerus fracture is still high. The overall complication rate was 53%, and the overall reoperation rate was 21% (Yetter et al., 2021). Type 13C fractures had significantly higher rates of fixation, also had significantly higher rates of all neuropathies and ulnar neuropathies than type 13B fractures. Furthermore Post-operative complications including infection, non-union, malunion, painful implants, heterotopic ossification, stiffness, and post-traumatic arthritis were recorded.

Stiffness of the elbow after surgery can arise from heterotopic ossification which risk factors have been reported in the literature, including concomitant head and central nervous system injury, delayed internal fixation, use of bone graft or substitute, extended post-operative immobilization, method of fracture fixation and number and position of the plates. Hence, appropriate rehabilitation and early mobilization can improve patient outcomes.

This patient came to the hospital soon after injury, taking into consideration the patient's age and his level of activity, time of injury, surgical treatment is the best option for the treatment. Early surgical treatment showed a better outcome compared to delayed treatment. Research reported six cases of malunion which were treated with open reduction and internal fixation. Two of them developed neurologic impairment, one developed a deep infection and four of them needed hardware removal due to irritation (Kinaci et al., 2016).

The olecranon osteotomy approach is performed for this patient, considering that this approach is the gold standard among surgical approaches to allow early mobilization. A case series studies of 5 patients showed that 3 of the patients treated with the olecranon osteotomy approach had higher mayo elbow scores than the other (Bramantya, 2016). However active exercises of the elbow, forearm, wrist, and hand also play role in good functional elbow outcomes after surgery.

Functional Outcome After Open Reduction and Internal Fixation in Intraarticular Distal Humerus Fracture: A Case Report

The normal range of flexion-extension of the elbow is 0°–145°. The functional range of motion required for daily activities is 30°–130° of flexion-extension and 50° of supination to 50° of pronation. Flexion of elbow up to 149° may be required for some activities like using a cell phone and typing on a keyboard. Stiffness of elbow is defined as flexion <120° and loss of extension >30° (Mittal, 2017). This relates to this patient's follow-up result three months and ten months after surgery whose range of motions is 130° of flexion, 100° of extension, and 85° of pronation and supination. In conclusion, the patient can reach his functional elbow movements, back to his work without pain, and be satisfied with the final result.

Conclusion

Distal humerus fracture management requires a carefully planned approach. Surgical management by internal fixation is the treatment of choice for these fractures considered for a satisfactory function. A painless and functional elbow can be expected if a proper surgical technique and early mobilization are performed.

References

- Amir, S., Jannis, S., & Daniel, R. (2016). Distal humerus fractures: a review of current therapy concepts. *Current reviews in musculoskeletal medicine*, 9, 199–206.
- Attum B, T. J. (2022). *Humerus Fractures Overview*. [Updated 2021 Aug 11]. In: *StatPearls [Internet]*. Treasure Island (FL): StatPearls Publishing; 2022 Jan-. <https://www.ncbi.nlm.nih.gov/books/NBK482281/>
- Beazley, J. C., Baraza, N., Jordan, R., & Modi, C. S. (2017). Suppl-8, M3: Distal Humeral Fractures-Current Concepts. *The open orthopaedics journal*, 11, 1353.
- Beharrie, A. W., Beredjikian, P. K., & Bozentka, D. J. (2004). Functional outcomes after open reduction and internal fixation for treatment of displaced distal radius fractures in patients over 60 years of age. *Journal of orthopaedic trauma*, 18(10), 680–686.
- Bramantya, I. D. M. (2016). *The Functional Outcome Approached of olecranon osteotomy and tricep V shaped incision procedure on intracondylar fracture of Humerus based on Mayo score*.
- Crean TE, N. S. (2022). In: *StatPearls [Internet]*. Treasure Island (FL): StatPearls Publishing. <https://www.ncbi.nlm.nih.gov/books/NBK531474/>
- Kinaci, A., Buijze, G. A., van Leeuwen, D. H., Jupiter, J. B., Marti, R. K., & Kloen, P. (2016). Corrective osteotomy for intra-articular distal humerus malunion. *Archives of Bone and Joint Surgery*, 4(2), 161.
- Massoud, A. H. A., & Naam, N. H. (2012). Functional outcome of open reduction of chronic perilunate injuries. *The Journal of hand surgery*, 37(9), 1852–1860.
- Mittal, R. (2017). Posttraumatic stiff elbow. *Indian journal of orthopaedics*, 51(1), 4–13.
- Patel, S. S., Mir, H. R., Horowitz, E., Smith, C., Ahmed, A. S., Downes, K., & Nydick, J. A. (2020). ORIF of distal humerus fractures with modern pre-contoured implants is still associated with a high rate of complications. *Indian Journal of Orthopaedics*, 54, 570–579.
- Peng, Y., Liu, J., Zhang, G., Ji, X., Zhang, W., Zhang, L., & Tang, P. (2019). Reduction and functional outcome of open reduction plate fixation versus minimally invasive reduction with percutaneous screw fixation for displaced calcaneus fracture: a retrospective study. *Journal of Orthopaedic Surgery and Research*, 14, 1–9.
- Savvidou, O. D., Zampeli, F., Koutsouradis, P., Chloros, G. D., Kaspiris, A., Sourmelis, S., & Papagelopoulos, P. J. (2018). Complications of open reduction and internal fixation of distal humerus fractures. *EFORT open reviews*, 3(10), 558–567.
- Van Dreumel, R. L. M., Van Wunnik, B. P. W., Janssen, L., Simons, P. C. G., & Janzing, H. M. J. (2015). Mid-to long-term functional outcome after open reduction and internal fixation of tibial plateau fractures. *Injury*, 46(8), 1608–1612.
- Yetter, T. R., Weatherby, P. J., & Somerson, J. S. (2021). Complications of articular distal humeral fracture fixation: a systematic review and meta-analysis. *Journal of Shoulder and Elbow Surgery*, 30(8), 1957–1967.